



ANDROGENIC AND SPERMATOGENIC POTENTIAL OF METHANOLIC EXTRACTS OF *TRIBULUS TERRESTRIS* IN REPRODUCTIVELY DISRUPTED MALE ALBINO RATS

Mahima Sharma, Dharmendra Arya, Kiran Bhagour and R.S. Gupta

Reproductive Physiology Lab, Centre of Advanced Studies, Department of Zoology, University of Rajasthan, Jaipur, Rajasthan 302004, India

Abstract

Pharmacologically, *Tribulus terrestris* (caltrop) holds the trait to cure sexual and reproductive disorders in Indian traditional medicinal system. To investigate the fact, effect of the Methanolic Extract of *Tribulus terrestris* (METt) on testosterone level and fecundity/fertility was evaluated in male rats after the incorporation of antifertility standard drug Sulphasalazine. Clomiphene citrate standard drug to enhance fertility was given at 10 mg/kg b.wt, for 60 days to compare the results. Sulphasalazine (SSZ) fed male rats showed a decrease in fertility in comparison to control group animals which were fed with the distilled water and later treated with clomiphene citrate and METt. METt treatment improved fertility (~75%), promote sperm motility and sperm density significantly. METt administration restored the serum LH, FSH and testosterone levels and reverse to standard range with a very a significant ($p < 0.01$) manner. Furthermore, histopathological evaluation confirmed improvement in spermatogenesis, increased germinal and interstitial cell count as well as restoration of testicular architecture observed in METt treated rats. METt showed a significant modulatory effect against SSZ induced reproductive disruption and proved to possess spermatogenic and androgenic potential thus justify its traditional use of the plant.

Keywords: *Tribulus terrestris*, methanolic extract, fertility enhancement, testicular, testosterone.

Introduction

WHO calculated approximately 60–80 million couple experience infertility worldwide at present and 10-40% are due to male factor. Human sperm quality declination increased globally in over past few decades noticeably (Sen *et al.*, 2017). Multiple of factors influence male fertility and declination of semen quality that may be environmental as well as occupational factors along with lifestyle practices (Sharma *et al.*, 2013). Normal Semen parameters include sperm concentration of 39 million sperms per ejaculate, 15 million spermatozoa/mL (Nand and Singh, 2015) with progressive motility of 32%. Now attentions are shifted from synthetic drugs to natural plant products or herbal medicines and their combinations as potent fertility enhancer (Dada and Ajilore, 2009). The present investigation was carried out to evaluate the fertility enhancing effectiveness of *Tribulus terrestris* in experimentally induced infertility in male rats. *Tribulus terrestris* plant belong to family Zygophyllaceae commonly known as Gokhru a herbaceous perennial flowering plant inhabitant to temperate and tropical regions of South Europe, Asia, throughout Africa and Australia. Among all *Tribulus* species *T. terrestris* (Mahato *et al.*, 1981), *T. alatus* (Temraz *et al.*, 2006) and *T. cistoides* (Achenbach *et al.*, 1994) have been phytochemically investigated for their isolated steroidal saponins. *Tribulus terrestris* is exclusively explored for isolated Kaempferol, kaempferol-3-glucoside, kaempferol-3-rutinoside and tribuloside (kaempferol-3- β -D-(6"-p-coumaroyl) glucoside) (Bhutani *et al.*, 1969). *T. terrestris* has been used as tonic, aphrodisiac, astringent, analgesic, anti-hypertensive, diuretic and urinary anti-septic (Kianbakht and Jahaniani, 2003).

The present investigation was designed to evaluate the fertility enhancing effect of the different levels of methanolic fruit extract of the *T. terrestris* in male albino rats.

Materials and Methods

Plant material and preparation of plant extract

T. terrestris fresh fruits were collected from Campus of Rajasthan University during period of March to May 2010

and identified and authenticated by the Department of Botany, University of Rajasthan, Jaipur, India. The shed dried fruits (500g) were crushed, powdered and extracted with the 70% methanol for 72 hours at b.p 60-80 in a soxhlet. A viscous brown material was obtained after the removal of methanol under reduced pressure, which turned dark in brown solid after washing with petroleum ether. Five hundred gram dried fruits yielded 25gm of dark brown solid.

Standard drugs

Sulphasalazine (SSZ) and Clomiphene citrate of BAL Pharm Ltd, India were used as standard drugs. Biochemical Parameters were estimated by using kits (Accurex Biomedical Pvt. Ltd. Mumbai, India).

Animals

Adult, Male albino rats of *Rattus norvegicus*, Wistar strain, 16-18 weeks old weighing between 150-160gm (Sengupta *et al.*, 2013) colony bred in polypropylene cages under standardized condition of humidity, temperature and 12 hr light/12hrdark period. Rats pallets feed (Ashirwaad Ltd.) and tap water ad libitum. Body weight of each animal in all groups was measured weekly to see the possible body weight changes throughout the experiments.

Ethical aspects

The Indian National Sciences Academy, New Delhi (INSA.2000), (26) guidelines were followed for research ethics, maintenance and the use of experimental animals. The approval of the study (Reg. No. 1678/GO/RE/S/12/CPCSEA) was done by ethical committee, Center for Advanced Studies, Department of Zoology, University of Rajasthan, Jaipur (India).

Experimental Methodology

Fertile healthy male rats were divided into 4 groups of 10 rats each. The daily dose of the plant extract was freshly dissolved in 0.5 ml of distilled water and administered to each treated animal every morning for 60 days. Group 1 had Control rats received 0.5ml/day of the distilled water. Group

2 Rats treated with the sulphasalazine standard drug to produce antifertility 100 mg/kg/day. Group 3 Rats of (group 2) treated with the clomiphene citrate standard drug for fertility enhancement at 50 mg/kg/day. Group 4 Rats of (group 2) treated with the *Tribulus terrestris* seed methanolic extract (MeTt) at 50 mg/kg/day. All groups were administered orally after treatment with SSZ for the duration of 60 days.

Fertility Test

On day 55-60, for mating experimentation the male rats were cohabited with proestrus females at a ratio of 1:3 (Rahman *et al.*, 2014). The presence of vaginal plugs and sperms in the vaginal smear in the next morning were considered positive mating. The mated females were sacrificed on day 16 of pregnancy to find the implantation sites.

Autopsy

Twenty-four hours after the last dosing, the males were weighed and autopsied by mild anaesthesia as per CPCSEA guideline, 2003 and all reproductive organs such as testes, cauda, seminal vesicles, ventral prostate and vas deferens dissected out, weighed and preserved in a deep freezer at -20°C for further biochemical and histopathological parameters analysis. Blood samples were collected by the cardiac puncture.

Fertility, Sperm density and motility

The fertility percentage was calculated from formula (Number of pregnant/Number of mated) \times 100. The sperm density was estimated in cauda epididymides and testis. Spermatozoa were collected by from epididymal tissues and then homogenized in 100ml normal saline (0.9% NaCl) and incubated at 37°C for 5-10 min to make the sperms fully detached. Sperm counting (no. \times 10⁶/ml) done by Neubauer haemocytometer. The sperm motility was determined by counting both motile and nonmotile spermatozoa per unit area (Prasad *et al.*, 1972).

Biochemical studies

Testicular tissue was assayed for protein, sialic acid, glycogen and cholesterol. Fructose analysis was done in the seminal vesicle. R.B.C, W.B.C counts, hemoglobin, haematocrit and the sugar was analyzed in Blood (Lowry *et al.*, 1951; Montgomery *et al.*, 1957; Warren *et al.*, 1959; Zlatkis *et al.*, 1953).

Serum hormonal studies

Serum protein, cholesterol, triglycerides, phospholipids and HDL-Cholesterol were determined.

Commercially available kits for enzyme-linked immunosorbent assay (ELISA) were used as standard protocol for estimation of sex hormone i.e testosterone, luteinizing hormone (LH), and follicle-stimulating hormone (FSH).

Histopathological studies

Tissues were fixed in Bouin's fluid, passed through series of ethanol and then through xylene and then embedded in paraffin. Paraffin embedded tissues were sectioned and stained with haematoxylin and eosin to assist in discrimination of the stages of the spermatogenesis. The sections were scanned under \times 400 magnifications (Abercrombie *et al.*, 1946).

Statistical Analysis

Data are expressed as mean \pm SEM and are analyzed by using one-way analysis of variance (ANOVA) followed by Duncan's multiple comparison test (Statistical Package for Social Sciences, SPSS, v21.0), at $p < 0.01$ values were considered to be significant.

Results

Effect of MeTt Toxicological studies

No abnormal signs or death of animal was noticed in any of the treated group. Most of the animals treated with 50 mg/kg/day METt exhibited enhanced growth and appetite with no apparent conditions of toxicity such as mortality, weakness, Lethargy and negative response for physiological behavior. Therefore, the METt can be safely used for therapeutic use.

Effect of MeTt body and reproductive organ weight

This weight gain of body and testis was however significantly increased treated in (METt) treated groups as shown in Table I. Significant ($P \leq 0.01$) weight gain was observed in the testicular weights in 50mg/kg bw group. SSZ administration did not cause any significant body weight gain when compared to control rats. The relative testicular weight was significantly ($P \leq 0.01$) higher in (METt) treated group when compared with clomiphene citrate treated animals.

Table I : Body and Reproductive organ weight

Treatment	Body Weight		Testes	Epididymides	Seminal Vesicles	Ventral Prostate
	Initial	Final				
	(g)					
Group-I : Control	184.65 \pm 3.42	205.67 \pm 2.13	1530.26 \pm 16.84	554.67 \pm 3.80	461.17 \pm 4.35	338.50 \pm 4.80
Group-II : Sulphasalazine 100mg/ kg /day	183.56 \pm 3.12	189.33 \pm 2.65	1396.67** \pm 18.56	469.17** \pm 6.45	389.17** \pm 3.12	289.17** \pm 2.61
Group-III : Clomiphene Citrate 10mg/kg/day	179.33 \pm 2.18	193.26 \pm 1.62	1491.67 ^a \pm 10.84	539.17 ^{a+} \pm 7.80	416.17 ^{a+} \pm 4.34	312.50 ^{a+} \pm 9.35
Group-IV: <i>Tribulus terrestris</i> fruit extract 50mg/kg/day	189.02 \pm 2.01	199.5 \pm 1.55	1502.50 ^{a+} \pm 10.83	498.17 ^a \pm 2.61	439.67 ^a \pm 3.37	293.17 ^a \pm 1.67

Effect of MeTt on Sperm Dynamics, Fertility

Fertility rate decreased drastically to (~35%) in SSZ treated group along with the other decreased fertility dynamics sperm density & motility. The progressive sperm motility in 50mg (MeTt) treated group significantly ($P \leq 0.01$)

increased up to 24% when compared to Sulphasalazine treated group in table II. The cauda sperm count was highly significant ($P \leq 0.01$) by 19% in treated group when compared with SSZ aided group as shown in Table II.

Table II: Sperm Dynamics, Fertility and Testosterone Levels.

Treatment	Sperm Motility (Cauda epididymides) (%)	Sperm Density (Million/ml)		Fertility (%)	Testosterone (ng/dl)	L.H	F.S.H
		Testes	Cauda epididymides				
Group-I : Control	73.67 ± 1.12	5.22 ± 0.07	5.03 ± 0.05	100%	4.55 ± 0.10	4.32 ± 0.07	6.52 ± 0.11
Group-II : Sulphasalazine 100mg/kg/day	54.67** ± 2.20	3.18** ± 0.16	2.45** ± 0.15	35.25%	2.88** ± 0.05	3.21** ± 0.07	5.20** ± 0.03
Group-III : Chlomephene citrate 10mg/kg/day	70.50 ^{at} ± 0.99	4.95 ^{at} ± 0.14	4.18 ^{at} ± 0.08	90.65%	4.25 ^{at} ± 0.06	4.05 ^{at} ± 0.04	6.36 ^{at} ± 0.08
Group-IV : <i>T. terrestris</i> fruit extract 50mg/kg/day	68.67 ^a ± 1.45	4.87 ^a ± 0.08	3.97 ^a ± 0.10	75.25%	3.95 ^a ± 0.09	3.79 ^a ± 0.69	5.68 ^a ± 0.16

Effect of MeTt on Serum Hormonal assay

Hormonal assay shows significant ($P \leq 0.01$) and highly significant increase in serum hormonal concentration testosterone, LH and FSH level of the treated group

compared to controlled rats as shown in Table II that was dramatically reduced when treated with SSZ previously.

Table III: Tissue Biochemistry

Treatment	Glycogen Testis	Cholesterol Testis	Protein Testis	Sialic acid		Fructose Seminal vesicle
				Testis	Cauda epididymis	
Group-I : Control	3.06 ± 0.12	8.30 ± 0.10	229.61 ± 6.10	5.35 ± 0.24	5.98 ± 0.20	6.33 ± 0.05
Group-II : Sulphasalazine 100mg/kg/day	2.16** ± 0.10	11.98** ± 0.30	177.50 ** ± 3.82	4.15 ** ± 0.12	4.62 ** ± 0.13	4.34** ± 0.12
Group-III : Chlomephene citrate 10mg/kg/day	2.98 ^{at} ± 0.15	9.76 ^{at} ± 0.18	219.83 ^{at} ± 3.37	4.85 ^{at} ± 0.06	5.55 ^{at} ± 0.14	6.02 ^{at} ± 0.05
Group-IV : <i>T. terrestris</i> fruit extract 50mg/kg/day	2.50 ^a ± 0.12	10.90 ^a ± 0.14	196.67 ^a ± 3.33	4.52 ^a ± 0.27	5.03 ^a ± 0.22	5.11 ^a ± 0.04

Data are represented as mean \pm SEM (n = 10). (*) ($p < 0.01$) statistically significant difference when compared with Normal control. (a) ($p < 0.01$) (^{at}) statistically significant and highly significant ($p < 0.001$) difference when compared with SSZ control.

Effect of MeTt on tissue Biochemical parameters

Significant ($p < 0.01$) reduction in Testicular sialic acid, protein, glycogen and fructose parameters were found while cholesterol concentration increased significantly in SSZ treated rats as compared to normal control rats. MeTt administration significantly altered concentrations back in to nearly normal ranges of glycogen, protein, cholesterol, fructose and sialic acid in reproductive tissues after comparing with SSZ treated rats shown in Table III.

Effect of MeTt on Histopathological parameters

The histopathological findings on the photomicrographs of testis showed degenerated shrank seminiferous tubules with scanty spermatocytes and lumen with few leydig cells in sections treated with SSZ as shown in figure 2 compared with control sections figure 1. However, chlomephene citrate (figure 3) and MeTt treated (figure 4) group show dense spermatocytes within the tubular lumens along with the recovered leydig cells.

Discussion

Methanolic extract of *T. terrestris* is claimed to increase the body's natural testosterone levels i.e positive effect on sperm qualities and thereby investigation showed the fertility enhancing activity of the plant fruits. All data confirmed the increased sperm motility counts, testosterone and positive changes in protein, cholesterol, ascorbic acid and the significant weight gain in all reproductive organs could be due to increased androgen biosynthesis i.e. rise in serum testosterone levels (Shetty *et al.*, 1997; Prins *et al.*, 1991). The rats SSZ treated not only increased structural deformity but also altered sperm motility and sperm density thus leads to male reproductive disruption (Sharma & Kalla, 1994; Raji *et al.*, 2003). MeTt treatment leads to rise in LH that consequently increase the number and proper functioning of Leydig cells. Leydig cell in turn support to increase testosterone level. The rise in level of testosterone enhances reproductive organs weight and functions (O'Donnel *et al.*, 1994). After treatment, enrichment of spermatogenic activities i.e. increase in sperm activities may be due to higher level of testosterone, which also supported the stimulation of Leydig cells (Zhang *et al.*, 2001). MeTt

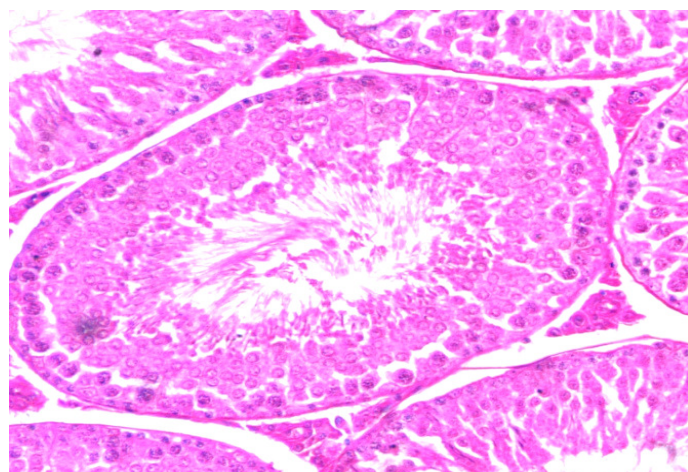
increased sialic acid secretion by the epididymal epithelium that is required for the maintenance of accurate functioning of sperm by facilitating their downward movement without friction (Singh and Chakravarthy, 2001). The improved seminal fructose also exhibits the enhancement of seminal parameters and eventually assisting better reproductive capacity. (Gonzales *et al.*, 1989). Sertoli cells proper activity is essential for accurate spermatogenesis. (Grootegoed & Baarends, 2004). In our Indian traditional medicinal system natural plant remedies are widely used at the place of synthetic drugs for the treatment of male with reproductive disorders (Sharma *et al.*, 2017). After screening in male albino rats, it could be concluded that it had effective spermatogenic and androgenic properties and *T. terrestris* fruits could be useful in fertility enhancing activity in males. These observations may be due to the peculiar compound present in the plant which is still need to be observed more.

Conclusion

The whole experiment confirmed that oral administration of *Tribulus terrestris* fruit extract acts significantly in case of fertility against drug (SSZ) induced male reproductive disorders and accredits for androgenic and spermatogenic nature just same as standard marketed drug clomiphene. Moreover the above done treatment also evidenced to improve all fertility parameters with no toxicity thus validating to be beneficial in fertility related disorders in close species such as human also.

Testicular photomicrographs of sections showing spermatogenesis stages (viewed under light microscope at ×400 magnification).

- (Figure 1) Normal control rats show a normal histoarchitecture of seminiferous tubule with all progressive stages of spermatogenesis. Sertoli cell and Leydig cell are also present
- (Figure 2) Sulphasalazine - treated rats with reduced size of seminiferous tubule and eruption in germ cells along with the degeneration in Leydig cells are also seen
- (Figure 3) Clomiphene citrate treated rat with recovered with increase in size of seminiferous tubule and in the number of spermatogenic cells
- (Figure 4) MeTt treated rat with mature spermatozoa in lumen of seminiferous tubule. A significant recovery in Sertoli and Leydig cells



(Figure 1)

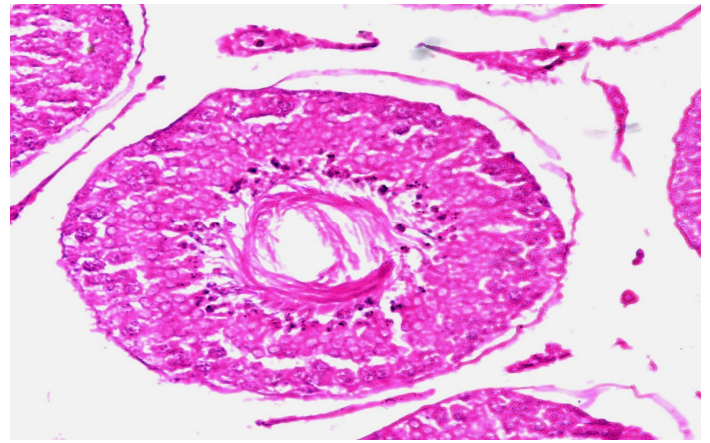


Figure 2

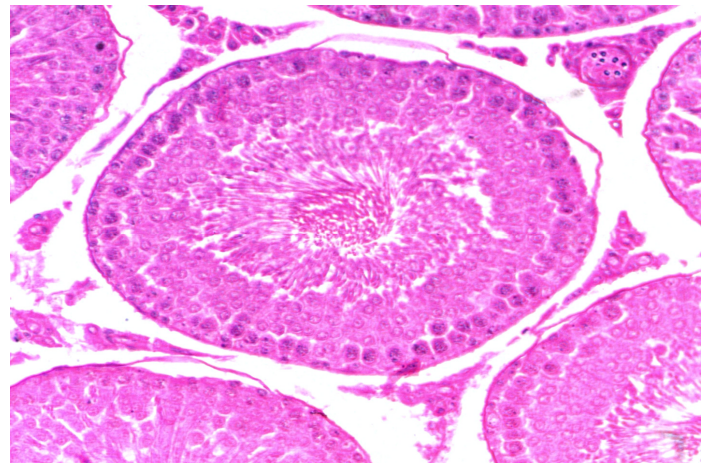


Figure 3

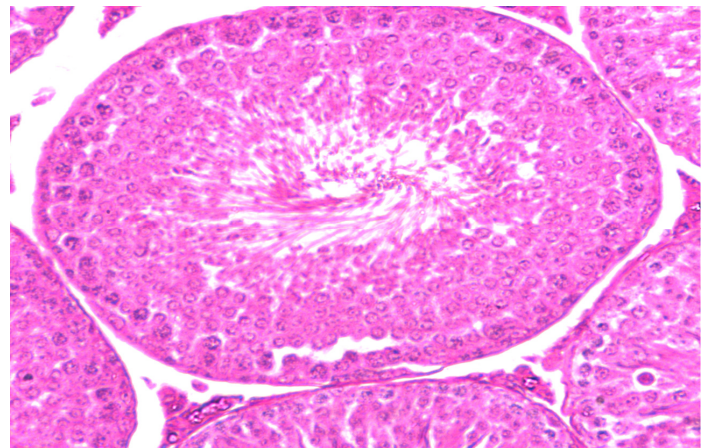


Figure 4

Reference

- Achenbach, H.; Hübner, H.; Brandt, W. and Reiter, M. (1994). Cardioactive steroid saponins and other constituents from the aerial parts of *Tribulus cistoides*. *Phytochemistry*. Apr, 35(6):1527-43.
- Dada, A.A. and Ajilore, V.O. (2009): Use of ethanol extracts of *Garcinia kola* as fertility enhancer in female catfish *Clarias gariepinus* broodstock. *International Journal of Fisheries and Aquaculture*, 1(1): 005-010.
- Gonzales, G.F. (1994). Corrected seminal fructose test. *Arch Androl*. 33: 17-22.
- Grootegoed, J.; Siep, A.M. and Baarends, W.M. (2004). Molecular and cellular mechanisms in spermatogenesis. *Baillieres Best Practice and Research Clinical Endocrinology and Metabolism*, 14: 331-343.

- Kianbakht, S. and Jahaniani, F. (2003). Evaluation of Antibacterial Activity of *Tribulus terrestris* L. Growing in Iran. *Iranian Journal of Pharmacology and Therapeutics (IJPT)*, 2(1): 22-4.
- Lowry, O.H.; Rosenburg, N.J.; Farr, A.L. and Randall, R.J. (1951). Protein measurement with Folin phenol reagent. *Journal of Biological Chemistry*, 193: 265-275.
- Mahato, S.B.; Sahu, N.P.; Ganguiy, A.N.; Kazumoto, M. and Toshio, K. (1981). Steroidal glycosides of *Tribulus terrestris* Linn. *J. Chem. Soc. Perkin. I.*, 9: 2405-2410.
- Montgomery, R. (1957). Determination of glycogen. *Archives of Biochemistry and Biophysics*, 67: 378-381
- Nand, K. and Singh, A.K. (2015). Trends of male factor infertility, an important cause of infertility: A review of literature. *J Hum Reprod Sci.*, 8: 191-196.
- O'Donnel, L.; McLachlan, R.I.; Wreford, N.G. and Robertson, D.M. (1994). Testosterone promotes the conversion of round spermatids between stages vii and viii of the rat spermatogenic cycle. *Endocrinology*. 135: 2608-2614.
- Prins, S.G.; Birch, L. and Greene, G.L. (1991). Androgen receptor localization in different cell types of the adult rat prostate. *Endocrinology*, 129: 3187-99.
- Sengupta, P. (2013). The laboratory rat: Relating its age with human's. *International Journal of Preventive Medicine*, 4: 624.
- Sengupta, P.E.; Borges, J.S. and Dutta, K.E. (2017). Decline in sperm count in European men during the past 50 years. *Hum Exp Toxicol*.
- Sharma, M.D.; Arya, K. and Bhagour, R.S. (2017). Natural aphrodisiac and fertility enhancement measures in males: A review. *Current Medicine Research and Practice*, 7: 51-58.
- Sharma, R.; Biedenharn, K.R.; Fedor, J.M. and Agarwal, A. (2013). Lifestyle factors and reproductive health: taking control of your fertility. *Reprod Biol Endocrinol.*, 11: 66.
- Sharma, R.K. and Kalla, N.R. (1994). Spermatozoal abnormalities and male infertility in the rat following sulfasalazine treatment. *International Journal of Fertility and Menopausal Studies*, 39: 347-354.
- Shetty, B.S.; Riar, S.S. and Kar, A.B. (1977). Androgenic control of epididymal function in rhesus monkey and rabbit. *Fert Steril*. 22: 674-81.
- Singh, S.K. and Chakravarty, S. (2001). Effect of nitrofurazone on the reproductive organs in adult male mice. *Asian J. Androl*. 3: 39-44.
- Temraz, A.; Omayma, D.E. and Hazem, K.A. (2006). Steroidal saponins from the aerial parts of *Tribulus alatus* Del. *Phytochemistry*, 67(10): 1011-8.
- Warren, L. (1959). The thiobarbituric acid assay of sialic acids. *Journal of Biological Chemistry*, 234: 1971-1975.
- Yinusa, R.; Toyin, S. and Akinsomisoye, S. (2005). Reproductive Functions in Male Rats Treated With Methanolic Extract of *Alstonia boonei* Stem Bark African Journal Biomedical Research. 8(2).
- Zhang, X.; Yamamoto, N.; Soramoto, S.; Takenaka, I. (2001). Cisplatin-induced germ cell apoptosis in mouse testes. *Arch Androl.*, 46: 43-49.
- Zlatkis, A.; Zak, B.A. and Boyle, J. (1953). A new method for the direct determination of serum cholesterol. *Journal of Laboratory and Clinical Medicine*, 41: 486-492.